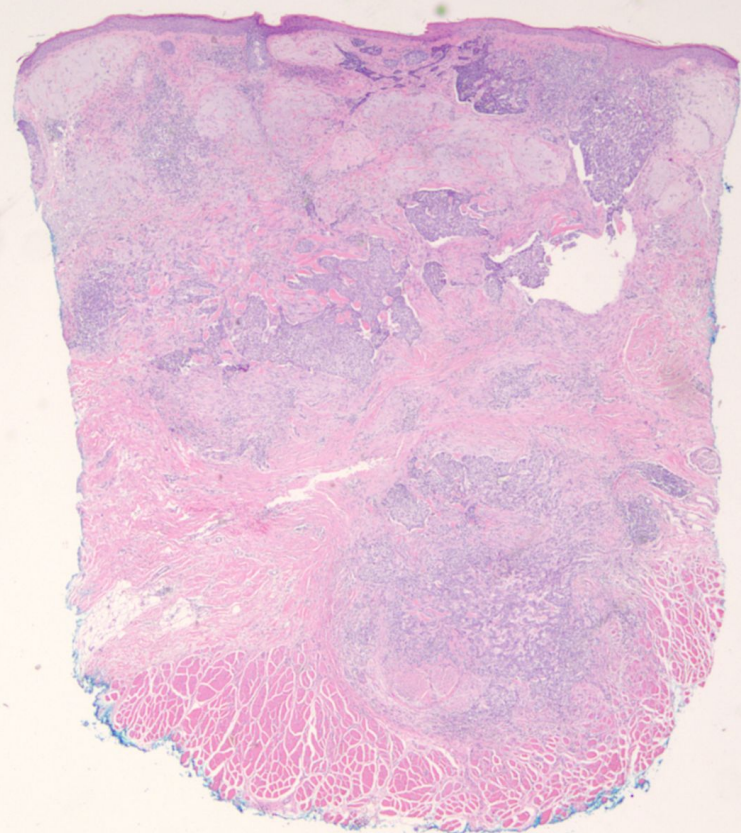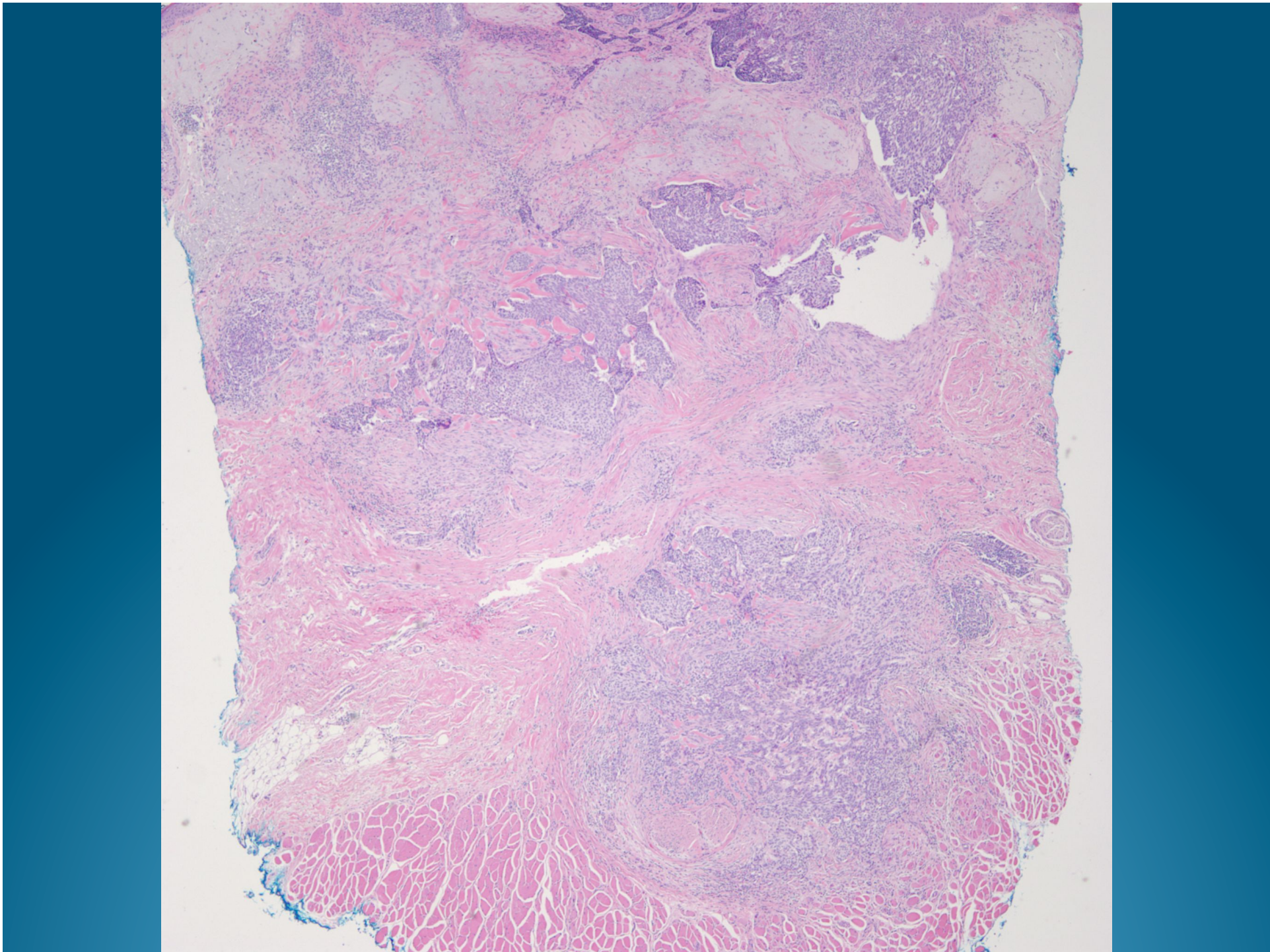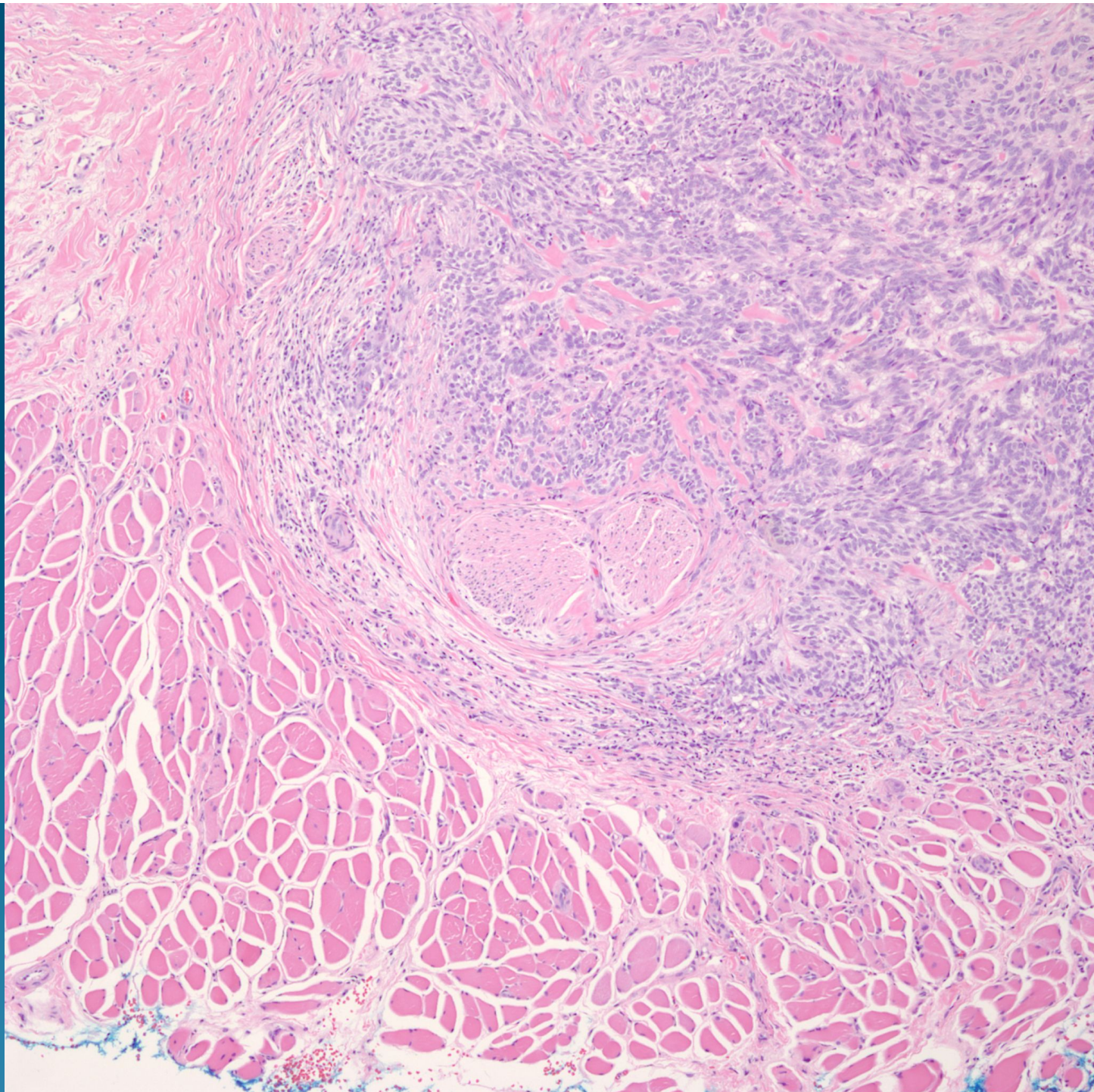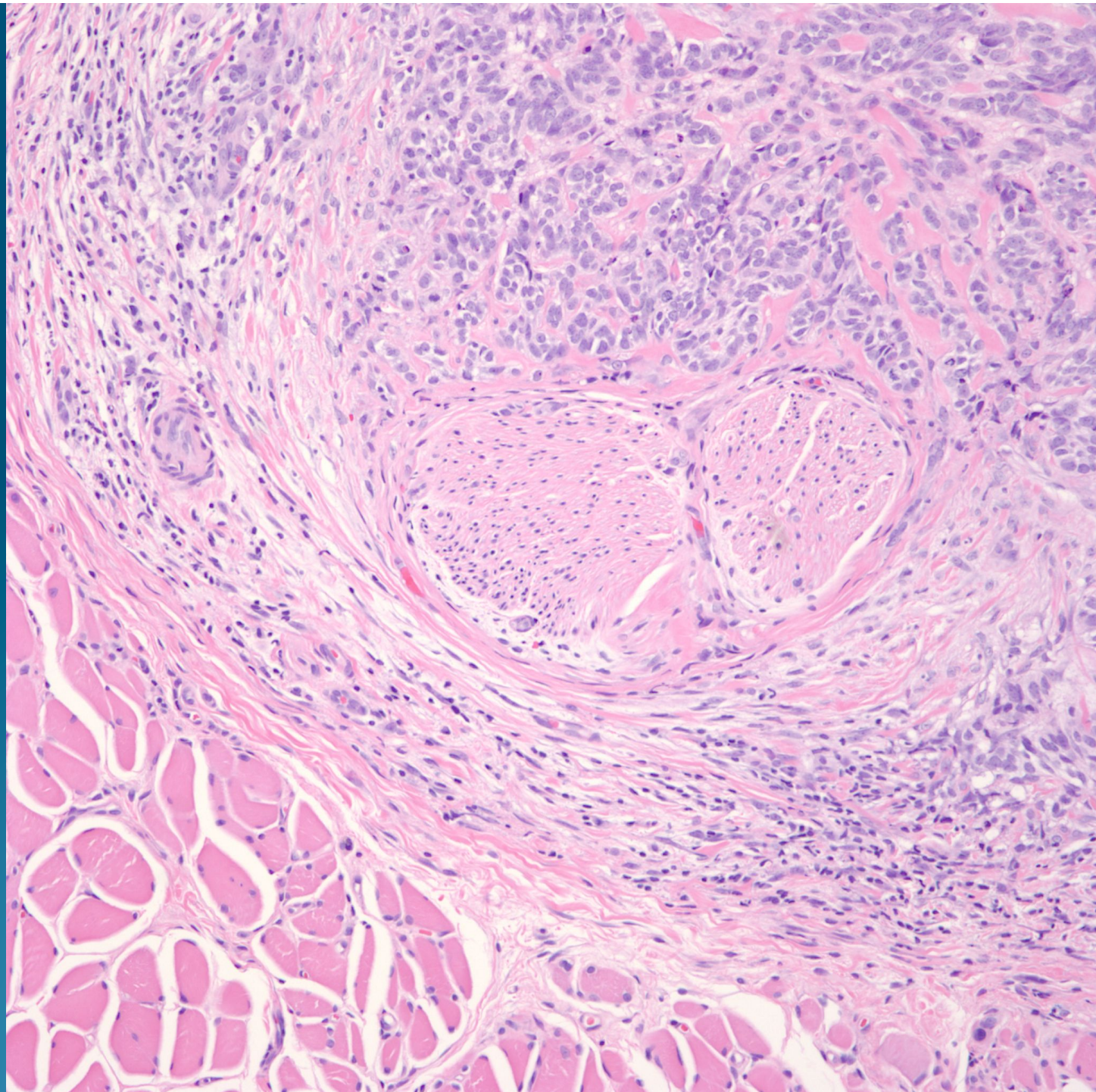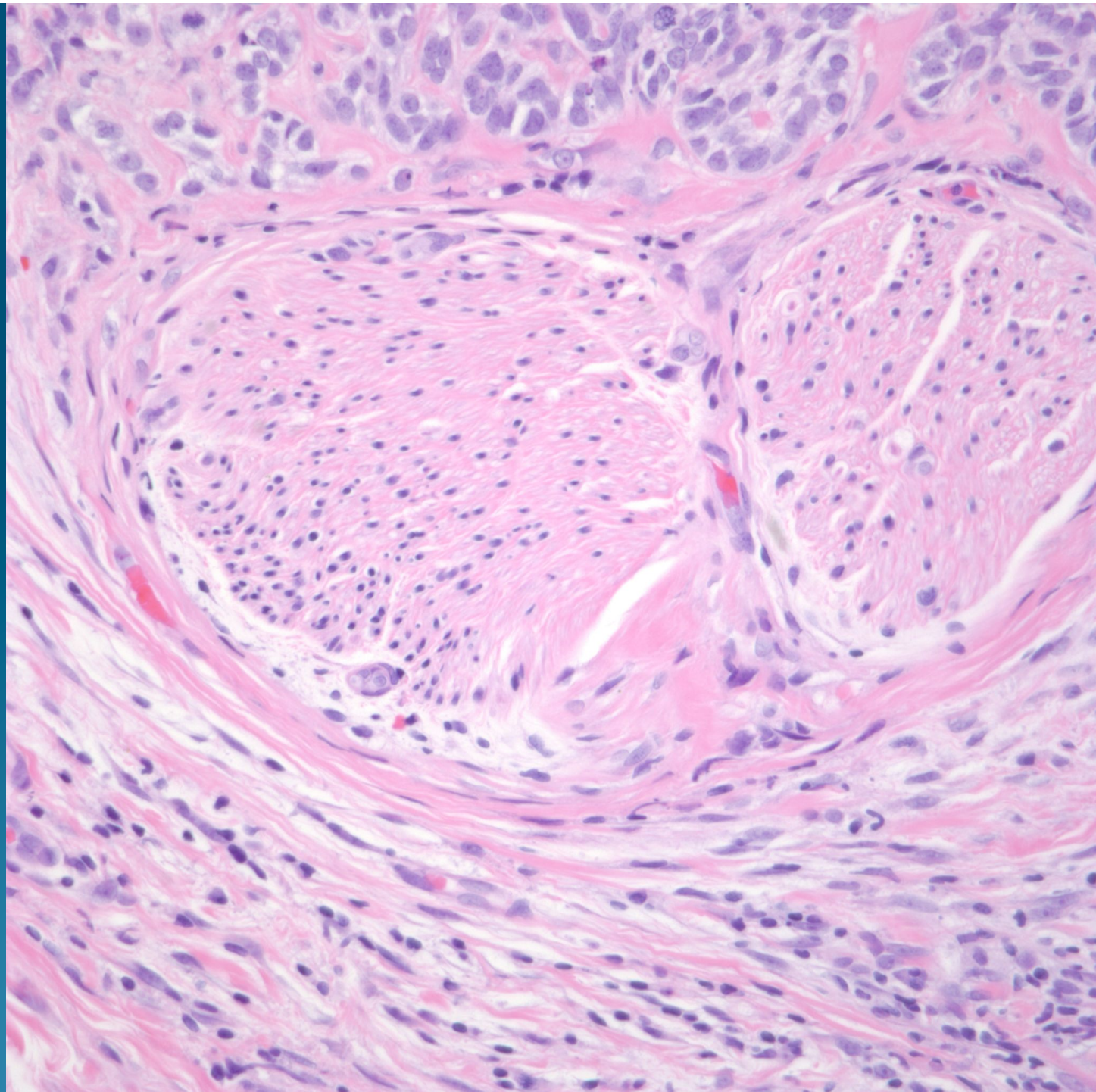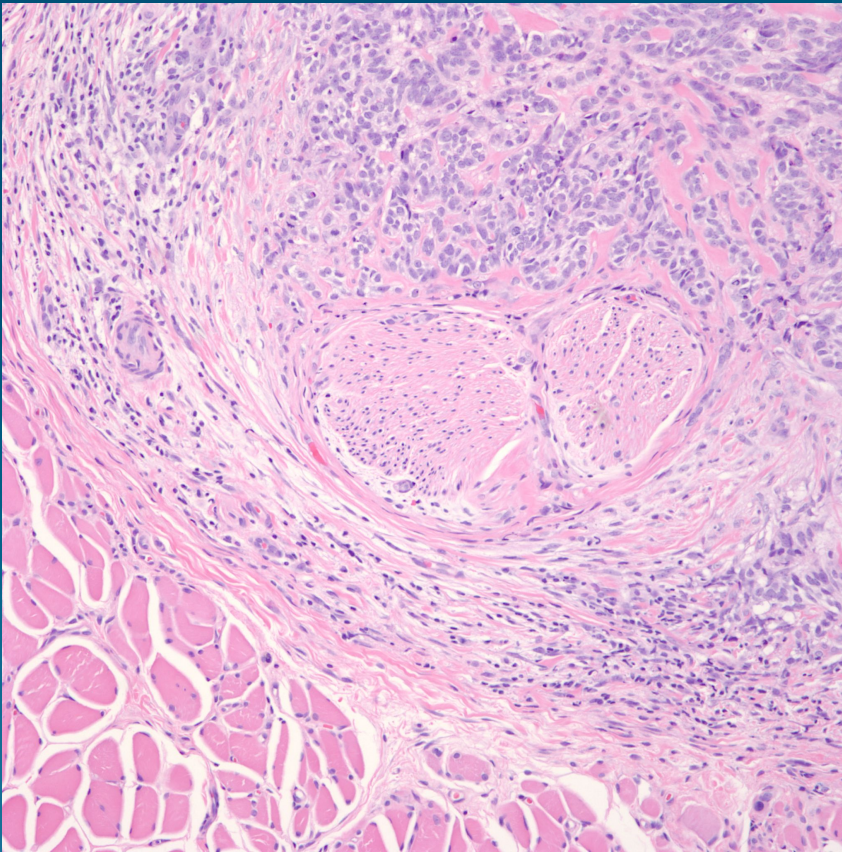


Basal Cell Carcinoma with Perineural Invasion

Pearls



- Presence may be associated with locally aggressive behavior
- May need S100 stain to highlight nerve fibers